

kidney news

Volume 1, Issue 3

December 1999

Introduction

The Christmas Edition.



MERRY CHRISTMAS

With more and more referrals for hypertension and investigation of causes of secondary hypertension, I thought I would dedicate this issue to hypertension; and in particular renal causes, and – of course – renal artery stenosis.

I wish you, members of your practice, and family a very Merry Christmas, and eventful New Year!

The year 2000 will bring much activity for me, but more on that in the next *Kidney News*.....

I am away from 25 December 1999 to 9 January 2000 inclusive.

Case Study

Ethyl, a 68 year old mother of 3, presents for her three monthly prescription of atenolol and felodipine. Hypertension history is 10years. Both parents had hypertension. Previously, Ethyl's BP has been well controlled at 136-148/72-88. Today it is 210/112. Examination findings are otherwise unremarkable.

She denies headaches. Confirms compliance. No new stresses.

She had an MI 7 years ago. In the past 2 months her angina has worsened, and she now gets angina walking to the shops. She claudicates at 150metres, previously 500m. She has stopped her regular 3km walks as a result.

She is an ex-smoker of 45 pack-years.

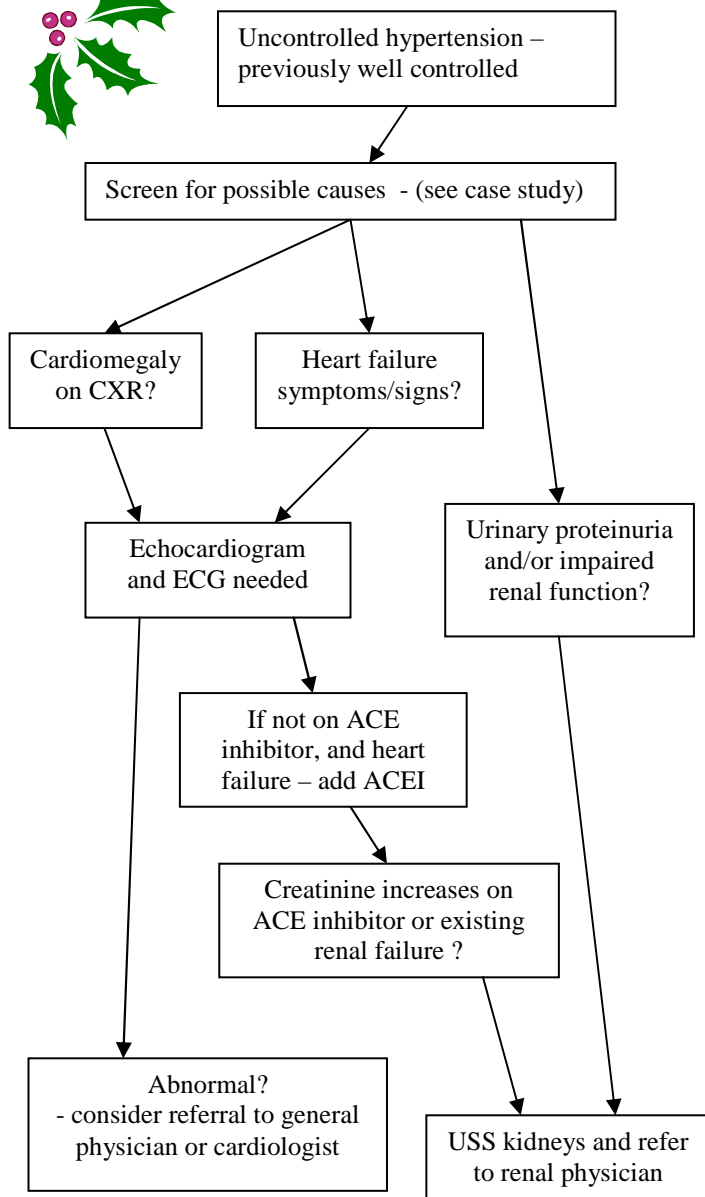
1. What is most likely the reason for increasing hypertension?
2. What other clues is/are there in the history?
3. What tests would you do?
4. What confirmatory test(s) is needed?

Problem is: Uncontrolled hypertension in a previously controlled situation.

1. Development of renal artery stenosis. The sudden deterioration may reflect the stenosis is finally critical.
2. Other risk factors: smoking history, presence of peripheral vascular and ischaemic heart disease. These two diseases are progressing. She probably has significant cerebrovascular disease. Dietary history may be useful – fats/lipids maybe a reversible contributing risk factor.
3. Full blood count (anaemia explaining worsening angina); renal function (hypertension and ?deterioration with worsening hypertension); cholesterol/lipids (other risk factor for vascular disease); MSU (?proteinuria – hypertensive damage). Ultrasound scan of kidneys (renal size – especially ?asymmetry). ECG. Chest radiograph and echocardiogram maybe appropriate (?damage from hypertension). CXR would be done on admission to hospital/on seeing the specialist. An echocardiogram important if worsening exercise tolerance supports heart failure – and need for ACE inhibitor. If ACE inhibitor needed for heart failure, then renal artery stenosis (despite the absence of an abdominal bruit) must be looked for (especially if creatinine elevated) and treated, so an ACE can be safely utilised.
4. Renal arteriogram if renal function normal. MRA (magnetic resonance angiogram) if renal impairment (creatinine > 0.15mM (certainly if above 0.2mmol/l).

WHAT'S IN HERE THIS TIME?

- 1 Introduction
- 1 Contents
- 1 Case study – hypertension
- 2 Approach to the patient with hypertension
- 2 How to contact me



Dr David Voss ED

Specialist Physician
Renal and Internal Medicine

Rooms

15 Aberfeldy Avenue, Highland Park, Auckland

Residence

13 Sprott Road, Kohimarama, Auckland 5

Contact on cellular phone

021 664664

Appointments

phone 09 5373578

Facsimile

021 699664

E-mail:

kidney@clear.net.nz

Qualifications

BSc (Biochemistry, Otago) 1981

MBChB (Otago) 1984

FRACP 1992

MRCP(UK) 1993

Interests

Investigation of renovascular disease and hypertension

Management of urinary tract infections

Investigation of urinary calculi

Investigation of proteinuria and haematuria

Investigation and management of impaired renal function.



OTHER POINTS FROM CASE STUDY

- needs vascular surgeon referral for claudication.
- *angiography of renal vessels and lower limbs could be done at same time.
- Impaired creatinine (above 0.15mM, especially above 0.2mM) increases risk of radiocontrast nephropathy. MRA maybe a better test in such patients.
- Aspirin should be added for CVD, IHD, and peripheral vascular disease.
- β -blocker may be continued in mild heart failure. Often beneficial in such IHD cases to persist with β -blocker. Moderate-severe heart failure, β -blocker would need to be stopped (maybe only temporarily).

